

HEINE Dermatoscopy Scabies Diagnostics

Synonym: Mange

Germ: Scabies mite (*Sarcoptes scabiei* var. *hominis*). Female scabies mites (0.3 – 0.5 mm in size) are visible to the human eye as a dot. They burrow tunnel-shaped trails into the skin's stratum corneum (approx. 0.5 – 5 mm per day), where they lay their eggs, from which the larvae emerge after approx. two to three days. The larvae then fan out across the skin surface. The mites can survive in the skin for approx. 30 – 60 days.

Incidence: Global, more frequently in winter. Transmission typically occurs from person to person, occasionally via textiles (bed linen, blankets, clothing). Outbreaks primarily in institutions where people live closely together.

Incubation period: Initial symptoms occur two to five weeks after becoming infected; in the case of re-infestation, eczematous skin lesions can occur after only one to four days due to pre-existing sensitization.

Skin areas primarily affected are areas with higher body temperature, such as the webs between the fingers and feet, the backs of the elbows, the axillary folds, the areas around the nipples, around the waist and umbilicus, buttocks, anal folds and perianal region, groins, ankles, inner edges of the feet and, in men, the shaft of the penis (typically elongated papules).

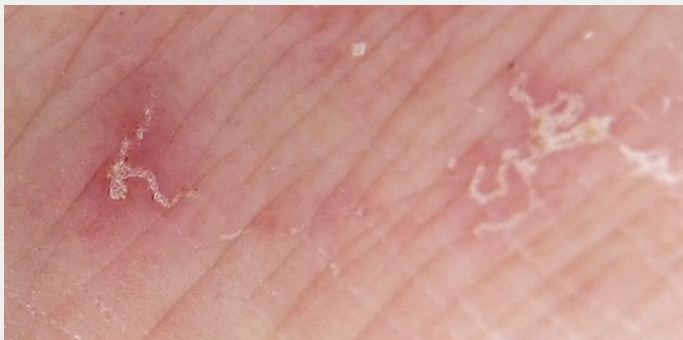

Fig. 1: Typical primary signs on mite infestation: Comma-shaped trails, generally in the form of irregular spirals, whitish and a few millimetres to 1 cm long, with a small vesicle (= mite) sometimes developing at the end.

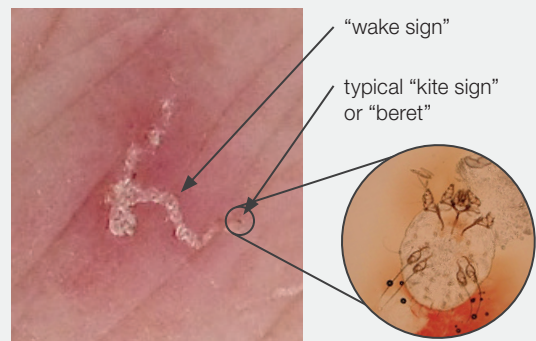


Fig. 2: Dermatoscopic findings: Typical is a brownish triangular structure ("kite sign", also called a "beret", corresponding to the head and breastplate of the mite) associated with an air-filled, intra-corneal tunnel system ("wake sign").

© Gratefully reproduced with approval of Dr. Christoph R. Löser, Skin Clinic, Ludwigshafen Medical Centre.

Signs and symptoms of the skin:

Typically for the primary manifestation of mites are the comma-shaped, irregular trails with a small vesicle at the end (Fig. 1 and 2). The secondary manifestations are caused by a cell-mediated immune response against mite faeces. It occurs as eczema like symptoms with disseminated, mite-free, erythematous and partially crusty papules, vesicles or papulovesicles. Typically this is accompanied by serious, sometimes generalised pruritus increasing at night and according excoriations.

Diagnostics:

- The dermatoscopic finding has proved to have the highest sensitivity (Walter B et al 2011, Löser C, 2011) (Fig. 2).
- The microscopic finding of mites, eggs or scybala in skin scrapings or in adhesive-tape test has the highest specificity.

Notification to authorities

Consider country specific regulations on notification requirements to governmental centres of disease control, in particular if scabies has been diagnosed in institutions.

The CDC, Center for Disease Control and Prevention in the US, recommends the following:

- Establish procedures for identifying and notifying at-risk patients and staff who are no longer at the institution.
- Ensure a proactive employee health service approach to scabies including providing information about scabies to all staff and providing dermatologic consultation for employees and, where appropriate, their household members.
- Maintain an open and cooperative attitude between management and staff.

Sources: www.cdc.gov/parasites/scabies/health_professionals/crusted.html

Löser C. Dermatologische Kleinwildjagd – Der Skabiesnachweis mittels Dermatoskop und Kanülenextraktion. *Akt Dermatol* 2011; 37(8/09): 287-288.

Walter B, Heukelbach J, Fengler G, Worth C, Hengge U, Feldmeier H. Comparison of dermoscopy, skin scraping, and the adhesive tape test for the diagnosis of scabies in a resource-poor setting. *Arch Dermatol*. 2011 Apr;147(4):468-73.